

## Using Socket Grafting for Correcting Poor Esthetics



Ara Nazarian, DDS  
Private Practice  
Premier Dental Center  
Troy, Michigan  
Phone: 248.457.0500  
Email:  
ara20002@comcast.net

The way dentistry is performed has changed dramatically in the past several years. New techniques, materials, and views have dictated alternative concepts. The introduction of bone grafting materials into dentistry is becoming widespread. Not only are these materials playing a crucial role for improving the treatment of bony defects caused by surgery, trauma, dental disease, and extractions, but are also improving the esthetics in restorative dentistry.<sup>1</sup> [QA: Edit okay?]

### Mechanisms of Bone Regeneration

Bone regeneration is accomplished via 3 different processes: osteogenesis, osteoinduction, and osteoconduction.<sup>2-5</sup> Osteogenesis is the formation and development of bone even in the presence of local undifferentiated mesenchymal stem cells. Osteogenic grafts can differentiate and facilitate the different phases of bone regeneration even in soft tissue, and activate more rapid bone growth. An osteogenic graft is an organic material that is derived from or composed of living tissue. Osteoinduction is the transformation of the undifferentiated mesenchymal stem cells into osteoblasts or chondroblasts through growth factors found only in living bone. Osteoinductive grafts enhance and facilitate, or extend normal bone regeneration even in places where it is normally not found. Osteoconduction is the process that provides a

bionert scaffold or physical matrix suitable for the deposition of new bone.<sup>2-5</sup> Osteoconductive grafts, which are often inorganic, allow bone apposition from existing bone or encourage differentiated mesenchymal cells to grow along the surface, but it does not produce bone formation when placed in soft tissue. All grafting materials have 1 or more of these 3 mechanisms of action. The mechanisms by which the grafts act are normally determined by their origin and composition.

### Alloplasts

The introduction of synthetic bone for hard tissue replacement has opened many new opportunities to the general dentist. Alloplasts or biocompatible synthetic materials have been used during the past 2 decades for grafting. High expectations have been placed on the use of this material, and recent advances have greatly improved the results in selected dental cases. Synthetic bone can be resorbable or nonresorbable, microporous (<350  $\mu\text{m}$ ) [QA: Is this correct?], macroporous (>350  $\mu\text{m}$ ) [QA: Is this correct?], or nonporous, crystalline or amorphous, granular or molded in form. The advantages of using this material include readily available, no donor site or in patient, sterile, stowable, safe and well tolerated. These materials are typically only osteoconductive, but all have some different properties which will determine the material that is best for a specific application.<sup>3,6</sup> There are mainly 3 groups of alloplasts:

ceramics (synthetic hydroxyapatite, tricalcium phosphate, glass); calcium carbonate; and composite polymers (resorbable and nonresorbable).<sup>7,8</sup>

Biopiant (Kerr Corporation) synthetic bone material is a patented copolymer derived from a proprietary process combining polymethylmethacrylate (PMMA) and polyhydroxyethylmethacrylate (PHEMA). Additionally, it contains very thin layers of barium sulfate (for radiopacity) and calcium hydroxide. It is highly porous, negatively charged, easy to handle and apply, graftable, and has been proven in clinical studies and tests to be osteoconductive.<sup>9</sup> Other synthetic bone materials on the market that may have some similar characteristics include Perioglass and NovaBone (NovaBone Products, LLC), Collograft (Zimmer), Actifuse (ApaTech, Inc), and Osteograft-0700 [QA: Who is the manufacturer?]. Biopiant material appears to permit more extensive ingrowth by surface area as a result of its microporous structure. It is unique because the spherical beads allow surrounding bone to grow into and integrate with the Biopiant material. This design characteristic of the material will promote new bone growth. Also, the hydrophilic nature of the material causes the uptake of blood at the site of use, thus, enhancing clot formation and tissue repair.<sup>7,8</sup>

The synergy of its components results in a unique combination of properties not previously seen in

any bone substitute material. The most important and unique characteristic is the negatively charged surface of -10 mV. Becker (University of Syracuse) and Salkind (Rutgers University) showed that such a negative charge facilitates and enhances bone healing and formation.<sup>7</sup> This charge also impedes the development of infection. Far from stating that the material is bacteriostatic or even bacteriocidal, because both the material and the bacteria have a negative surface charge, the bacteria does not easily colonize on the surface of the polymer. This charge also allows the polymer to adhere to bone, to attract the pluripotential precursor cells that will form osteoblasts to its surface, and to adhere to metal as well as enhancing osteointegration with implants.<sup>6,9,10</sup> The negative charge also enables the material to be used without any barrier membrane. This material acts as a membrane, but alone not mixed with autogenous bone and wetted with bleeding marrow, forms initially dense fibrous tissue under the gum flap. Together with its substantial compressive strength (up to 1,800 psi) it provides every clinician with possibilities never seen before.

Biopiant synthetic material has been reported effective for after dental applications such as ridge preservation after extraction, ridge augmentation, periodontal defects, apical lesions, cysts, granulomas, sinus lifts, and placement of immediate postextraction or delayed implants.<sup>6,9,10</sup>



Figure 1—A preoperative full-face image.

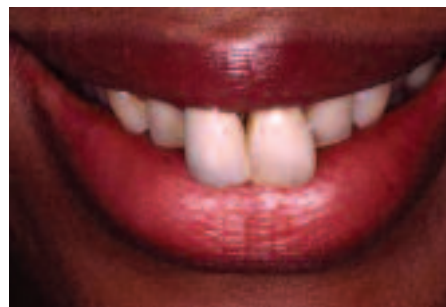

Figure 2—A preoperative smile.

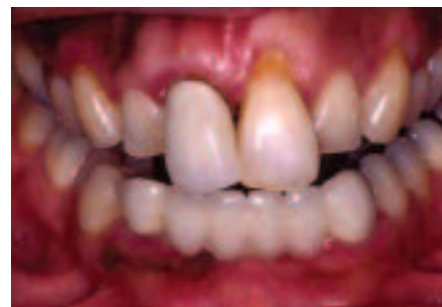

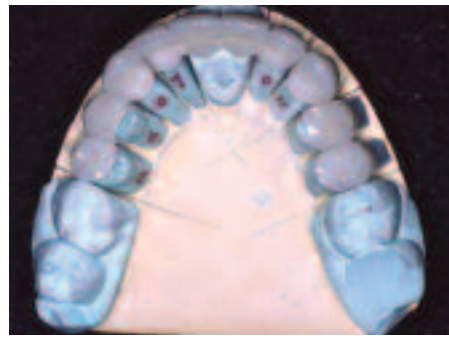
Figure 3—A preoperative retracted view.

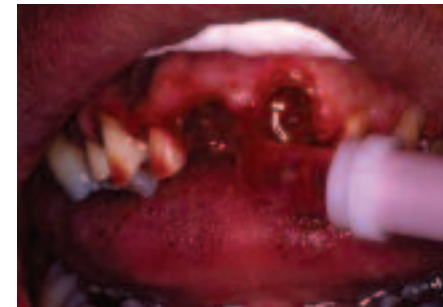
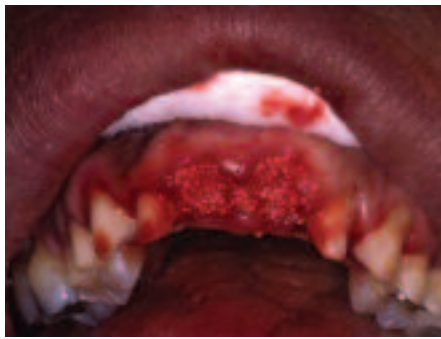
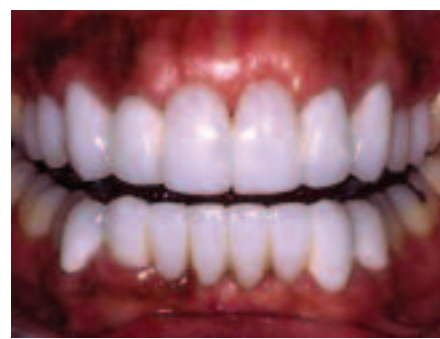Figure 4—The wetting of Biopiant material.



**Figure 5**—The placement of Biopiant synthetic bone.



**Figure 6**—IPS d-Sign restorations from Burbank Dental Laboratory.



**Figure 7**—A postoperative retracted view.



**Figure 8**—A postoperative full-face image.

## Clinical Example

A 43-year-old woman presented with a chief complaint of an unesthetic smile (Figures 1 and 2). She desired straighter, whiter teeth that would enhance her overall appearance. A clinical examination revealed a porcelain-fused-to-metal (PFM) restoration on tooth No. 8, and multiple failing interproximal composite restorations on her remaining maxillary anterior teeth. Tooth No. 9 exhibited 2 mm of recession with cervical wear (Figure 3). Her lower anterior teeth were previously restored with a fixed partial denture extending from teeth Nos. 22 to 27. The patient did complain of some mobility and discomfort on tooth No. 8. Upon radiographic examination, it was evident that tooth No. 8 was experiencing internal resorption that was nonrestorable.

All risks, benefits, and alternatives were reviewed with the patient regarding treatment. It was decided to extract teeth Nos. 8 and 9, place Biopiant synthetic bone grafting material, and restore the area to health, esthetics, and function. The premolars would also be restored with veneers to broaden the patient's smile. Her lower dentition would be restored with a new fixed partial denture and some veneers in the premolar region. The material of choice for her PFM restorations as well as veneers would be IPS d-Sign (Ivoclar Vivadent, Inc).

On her first appointment, teeth Nos. 4, 5, 12, and 13 were prepared for wrap around veneers, whereas teeth Nos. 6, 7, 10, and 11 were prepared for full-coverage crowns. Teeth Nos. 8 and 9 were to be extracted because of their current conditions and excessive protrusion facially. The 2 maxillary centrals (teeth Nos. 8 and 9) were atraumat-

ically removed. Because the buccal plate was very thin care was taken not to fracture it during extraction, and not to compress it after extraction. Any soft tissue debris was removed from the tooth socket. If the socket has a cystic lesion, then the bone surrounding the soft tissue lesion would be roughened to stimulate bleeding. The customized tip on the Biopiant syringe was inserted into the socket to draw blood into it (Figure 4). This blood contained the progenitor cells important in the regeneration of bone in the socket. The material was then syringed and condensed into the extraction site to the crest of bone. When wet the material stuck together allowing it to stay where it was placed (Figure 5). Because there was enough soft tissue present it was sutured together to allow for primary closure. If there is not enough soft tissue to close the wound cut a piece of cellulose Gelfoam (Pharmacia & Upjohn) to fill the coronal portion of the soft tissue void.<sup>1</sup>

The site was then covered with Biofoil (Kerr Corporation) oral bandage while a Sil-Tech (Ivoclar Vivadent, Inc) putty matrix of the diagnostic wax-up was filled with temporary material and used to fabricate the provisional restoration. Using composite, the pontics of the temporary were extended an extra 1.5 mm apically to facilitate ovate pontic sites for the definitive prosthesis. This shape would help to support the papillary and marginal gingiva in their preextraction positions by exerting horizontal pressure below the crest of the gingival tissues. The interproximal bone was maintained and the ovate pontic created primary closure over the extraction site. The Biofoil was then removed and the temporary

was cemented into place with TempBond Clear (Kerr Corporation).

The extraction sites (2 weeks later) healed beautifully, still maintaining ridge height and width but now with custom ovate pontic sites. Impressions were taken for the final restorations with a fast setting polyvinylsiloxane material Take 1 Super Fast (Kerr Corporation). The longer you wait after the ridge preservation procedure before making the final tooth preparations the more mature the bone will be in the extraction site, and the more predictable your esthetic results will be.<sup>1</sup> Ideally, a dentist would prefer 2 months the final tooth preparations are made; however, in this particular case the patient did not want a removable temporary, and her esthetic concerns were addressed immediately. If placing an implant, it is advisable to wait 1 year to allow for bone maturation.

During the laboratory phase, the full-arch polyvinylsiloxane impressions were used to pour a master model which the restorations were based on. A silicone incisal matrix of the provisional restorations was created to guide the placement of incisal effects and edge position in the subsequent porcelain buildup. With specific instructions and communication using photographs, diagnostic models and wax-ups, the laboratory technician had the necessary information to create an ideal smile (Figure 6).

As seen in the postoperative photographs, the overall health and structure of the soft tissue and restorations were very good (Figure 7). The patient was very satisfied with the final results (Figure 8). **[QA: Acknowledgment was moved to the end]**

## Conclusion

Postextraction ridge preservation and bone maintenance are important components of any successful practice. The use of extraction socket grafting reaps many benefits for the provider and the patient. Hemostasis, minimal postoperative infection, and establishing the groundwork for restorative and implant procedures are some of the advantages of this Biopiant grafting material. Esthetics and proper function can best be accomplished when the foundation is present for the final replacement of teeth. Together with increases in practice revenue this protocol is a win-win situation for everyone. ■

## Acknowledgment

A special thanks to Burbank Dental Laboratory for their excellent laboratory work and guidance in this challenging case.

## References:

1. Christensen GJ. Ridge preservation: why not? *J Am Dent Assoc.* 1996;127(5):669-670.
2. Gross JS. Bone grafting materials for dental applications: a practical guide. *Compend Contin Educ Dent.* 1997;1013-1038.
3. Misch CE, Dietsch F. Bone-grafting materials in implant dentistry. *Implant Dent.* 1993;2(3):158-167.
4. Lane JM. Bone graft substitutes. *West J Med.* 1995;163(6):565-566.
5. Tatum OH Jr. Osseous grafts in intra-oral sites. *J Oral Implantol.* 1996;22(1):51-52.
6. Boyne PJ. Use of HTR in tooth extraction sockets to maintain alveolar ridge height and increase concentration of alveolar bone matrix. *Gen Dent.* 1995;43(5):470-473.
7. Huys WJ. Hard tissue replacement. *Dentists News.* 2002;13-20. [QA: Please verify reference]
8. Isaksson S, Alberius P, Klinge B. Influence of three alloplastic materials on calvarial bone healing. An experimental evaluation of HTR-polymer, lactomer beads, and a carrier gel. *Int J Oral Maxillofac Surg.* 1993;22(6):375-381.
9. Szabo G, Suba Z, Divinyi T, et al. HTR polymer and sinus elevation: a human histologic evaluation. *J Long Term Eff Med Implants.* 1992;2(1):81-92.
10. Rosenlicht J. Immediate postextraction placement of an alloplast and titanium screw implant: a seven-year case presentation. *Pract Periodontics Aesthet Dent.* 1993;5(9):53-54.